

# DYSPLASTIC GANGLIOCYTOMA IN PEDIATRIC AGE GROUP WITH ACUTE PRESENTATION

Afifa Afsar,<sup>1</sup> Manzar Hussain,<sup>1</sup> Sadaf Nasir<sup>2</sup>

<sup>1</sup> Department of Neurosurgery, Liaquat National Hospital (LNH), Karachi, Pakistan.

<sup>2</sup> Department of Radiology, Liaquat National Hospital (LNH), Karachi, Pakistan.

PJR January - March 2024; 34(1): 37-40

## ABSTRACT

Dysplastic gangliocytoma (Lhermitte-Duclos disease, LDD) is a rare hamartomatous lesion of the cerebellum, characterized by thickening of the molecular and granular cell layers. We present a case of a 5-year-old boy with LDD, presenting with headache, vomiting, and fever. Imaging revealed a hypodense lesion in the left cerebellar hemisphere causing mass effect and hydrocephalus. MRI depicted abnormal signal intensity and characteristic enhancement patterns with tiger stripe appearance. Surgical intervention with ventriculoperitoneal shunt placement resulted in symptom resolution. LDD's natural history and management remain unclear, warranting further investigation in pediatric cases. This case highlights the importance of considering LDD in pediatric patients presenting with cerebellar lesions.

**Key words:** Dysplastic gangliocytoma, Lhermitte-Duclos disease, hydrocephalus, tiger stripe.

## Introduction

Dysplastic gangliocytoma (Lhermitte-Duclos disease, LDD) was first described by Jacques Jean Lhermitte and P. Duclos in 1920.<sup>1</sup> LDD is a hamartomatous lesion in the cerebellum. It may be associated with a growing lesion in the posterior fossa, increasing intracranial pressure, obstructive hydrocephalus and focal neurological deficits. The pathogenesis of this disease is still not fully understood. However, pathologically, it is characterized by the thickening of the molecular and granular cell layers of the cerebellar cortex with a slow progression. As based on our literature search, approximately 33 pediatric LDD cases were reported in the literature and 11 of them are under 10 years old.

## Case Presentation

We had a 5 year old boy, admitted via emergency

with complain of headache and vomiting and undocumented fever for last ten days. On examination, patient had a GCS of 15/15, he was drowsy yet arousible. There was no gross motor deficit. No signs of cerebellar dysfunction, except a positive Romberg's test on the left side.

CT brain plain was performed, which showed a hypodense lesion in the region of left cerebellar hemisphere causing mass effect and compression over the fourth ventricle. He was administered steroid and MRI brain with gadolinium was performed. It showed an abnormal high signal intensity lesion involving cortex and white matter of left cerebellar hemisphere and vermis, which appeared iso to low intensity T1 and high on T2 weighted image representing vasogenic edema. On contrast study, there was marked enhancement of cerebellar folia noted with characteristic tiger stripe or cordrouy pattern

**Correspondence** : Dr. Afifa Afsar  
Department of Neurosurgery,  
Liaquat National Hospital (LNH),  
Karachi, Pakistan.  
Email: sadaf.hoseyn@gmail.com

Submitted 2 February 2024, Accepted 9 February 2024

noted. Patient underwent Right sided ventriculo-peritoneal shunt placement, due to the mass effect and subsequent hydrocephalus caused by the cerebellar mass. clinical follow up 2 weeks showed resolution of symptoms. Parents were advised to bring the patient on yearly follow up for the next 3-5 years.

## Discussion

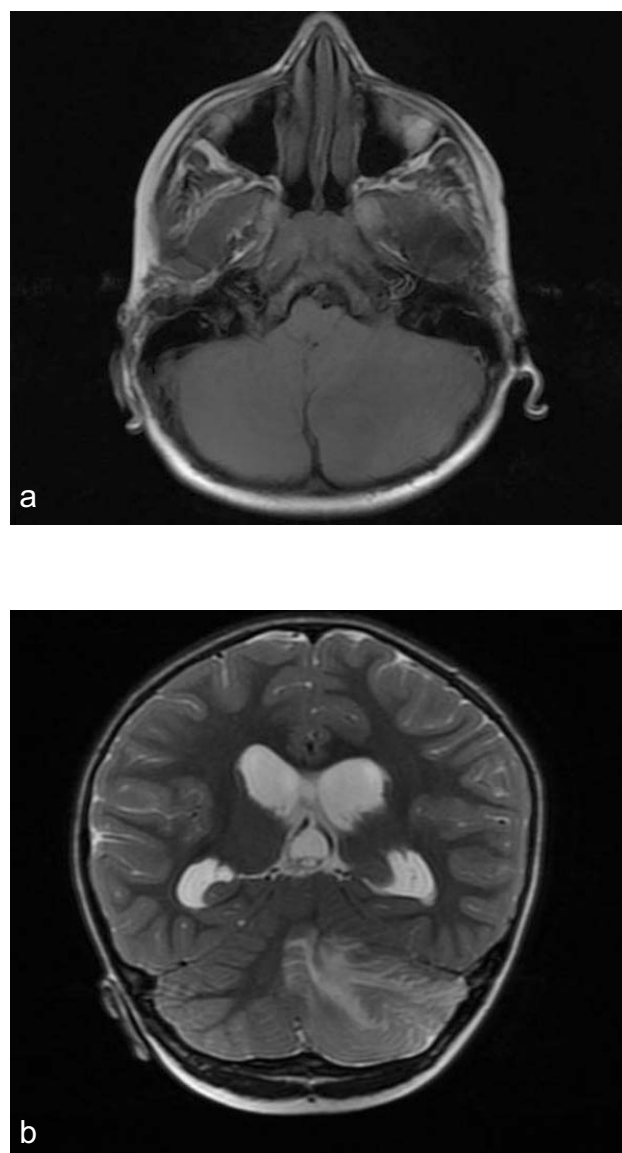
LDD is a rare hamartomatous lesion that typically affects the cerebellar cortex. It is typically found in the infratentorial region of the cerebellum. The natural history of LDD is not well-known, and there is limited information available. Some reports suggest a relatively long natural history, raising the possibility that LDD should be considered more as a neoplastic lesion than a hamartoma. LDD may be associated with Cowden syndrome in 80%, characterized by multiple hereditary hamartomas and neoplasms of breast, thyroid, genitourinary tract, and endometrium. DNA analysis is recommended in pediatric cases to rule out Cowden syndrome.<sup>2</sup> In pediatric patients, LDD does not involve PTEN mutation as seen in majority young and adult patients, and does not affect tissues outside the central nervous system, and the classic phenotype of Cowden syndrome is not present; similar features were found in our case, which suggests that pediatric LDD is a distinct entity from adult LDD and requires further investigations.<sup>3</sup>

The epidemiology of LDD remains unclear, with over 300 cases being reported worldwide. Age group commonly affected lies between 2<sup>nd</sup> and 4<sup>th</sup> decades of life, and its occurrence in the pediatric age group is very rare, like our case involves a 5-year-old patient. There is no gender predilection noted in these patients.<sup>4</sup> Histopathological findings are characterized by the absence of a Purkinje cell layer, increased myelination of axons in the molecular layer, hypertrophy in the granular cell layer, and atrophy in the cerebellar white matter.

Patients may be asymptomatic or present with signs of raised intracranial pressure, like headache, nausea, vomiting, and papilledema.<sup>2</sup> Other symptoms may include cerebellar ataxia and visual disturbances.<sup>7</sup>

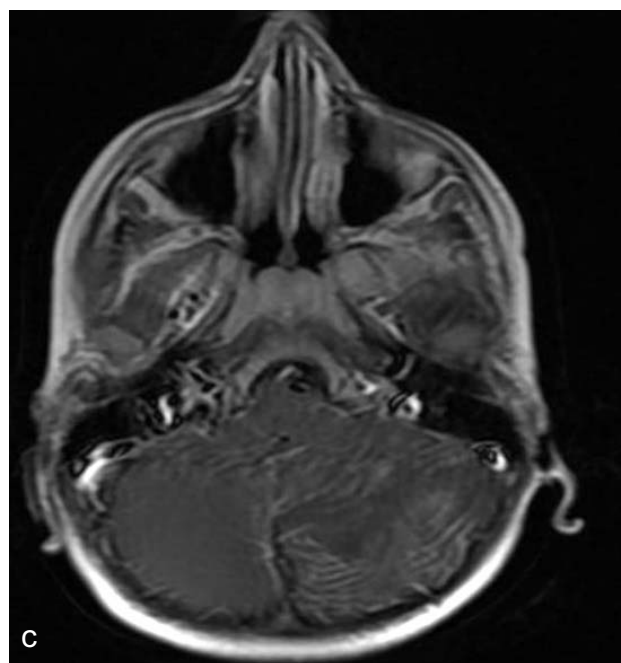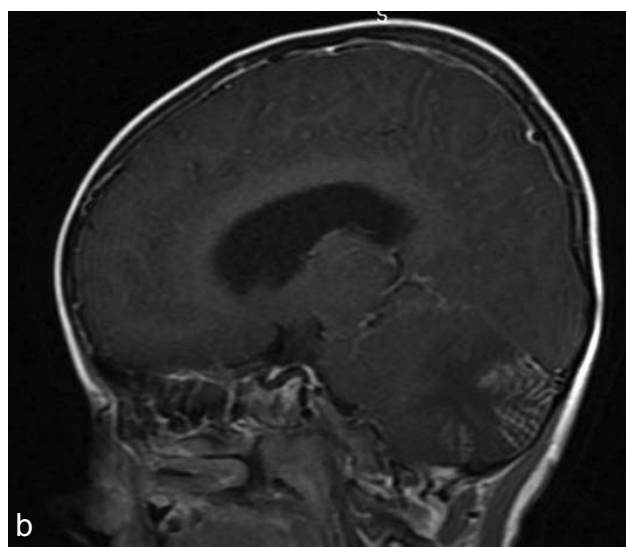
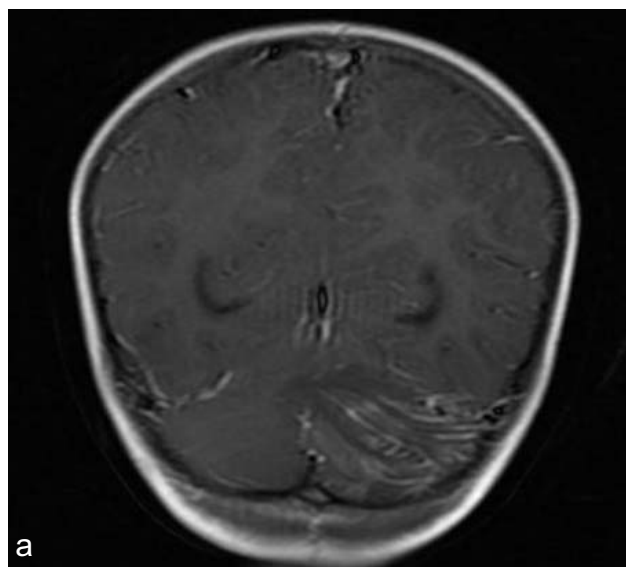
Radiological findings usually comprise of a large hypodense mass that compresses the 4<sup>th</sup> ventricle,

causing obstructive hydrocephalus on a computed tomography scan. Cranial MRI characteristically depicts a unilateral, T1-weighted hypointense, T2-weighted heterogeneous hyperintense signal mass lesion at the posterior fossa.<sup>5,6</sup> LDD may exhibit a characteristic "striated pattern" or "tiger-striped" appearance in MRI. Pseudotumoral hemicerebellitis (PTHC) can mimic LDD, and post-contrast enhancement with Choline peak in MR spectroscopy may suggest PTHC.<sup>6</sup> Medulloblastoma and Rosai-Dorfman granuloma are mentioned as rare entities that can be considered in the differential diagnosis.



**Figure 1a,b:** Axial T1, and Coronal T2 weighted image, showing the same findings.

Due to the rarity of the lesion there is no definitive consensus on its management. There is however a reported incidence of malignant transformation noted in these patients into medulloblastoma.<sup>4</sup> Despite that majority of the case followed for long periods, like 5-8 years have not shown any worsening or progression of symptoms, owing to the benignity of the lesion. Surgical treatment has traditionally been the primary option for LDD. Surgical intervention for LDD was described in 1937 by Christensen, who reported a patient with LDD who underwent surgery and was discharged from the hospital without complaints.<sup>9</sup> In cases where surgery is not feasible, such as involvement of the entire cerebellum, alternative therapies like rapamycin have been attempted.



**Figure 2a,b,c:** Coronal, sagittal and axial post contrast images, showing the characteristic tiger stripe pattern involving left cerebellar hemisphere

**Conflict of Interest:** None

## References

1. Lhermitte J, Duclos P. Sur un ganglioneurome diffuse du cortex du cervelet. Bulletin de l' Association Francaise pour l' etude du. Cancer (Paris). 1920; **9**: 99-107.
2. Pregøntegui-Loayza, I., Apaza-Tintaya, A., Ramirez-Espinoza, A., Mayo-Simón, N., & Toledo-Aguirre, M. (2021). Lhermitte-Duclos Disease in Pediatric Population: Report of 2 Cases. *Pediatric Neurosurgery*, **56**(3): 279-85.
3. Abel TW, Baker SJ, Fraser MM, Tihan T, Nelson JS, Yachnis AT, et al. Lhermitte-Duclos disease: a report of 31 cases with immunohistochemical analysis of the PTEN/AKT/ mTOR pathway. *J Neuropathol Exp Neurol*. 2005; **64**(4): 341-9.
4. Auedlaed Alanazi1, Tariq Alanezi1, Ziyad Fahad Aljofan1, Alwaleed Alarabi1, Sherif Elwatidy 2.

---

Lhermitte Duclos disease: A systematic review.  
29-Sep-2023; **14**: 351.

5. Wu CH, Chai JW, Lee CH, Chen WH, Lee T, Chen CC. Assessment with magnetic resonance imaging and spectroscopy in Lhermitte-Duclos disease. *J Chin Med Assoc* 2006; **69**: 338-42.
6. Shin JH, Lee HK, Khang SK, Kim DW, Jeong AK, Ahn KJ, et al. Neuronal tumors of the central nervous system: Radiologic findings and pathologic correlation. *Radiographics* 2002; **22**: 1177-89.
7. Dutta G, Singh D, Saran RK, Singh H, Srivastava AK, Jagetia A. Childhood Lhermitte-Duclos disease progressing to medulloblastoma in bilateral cerebellar hemispheres: Report of unusual case. *World Neurosurgery* 2018; **117**: 344-9.
8. PØrez-Nøæez A, Lagares A, Ben tez J, Urioste M, Lobato RD, RicoyJR, et al. Clinical article Lhermitte-Duclos disease and Cowden disease: clinical and genetic study in five patients with Lhermitte-Duclos disease and literature review. *Acta Neurochirurgica*. 2004; **146**: 679-90.
9. Christensen E. About ganglion cell tumors in the brain. *Virchows Arch Pathol Anat Physiol Klin Med*. 1937. **300**: 567-81.